




ESD

Endoscopic Submucosal Dissection

— Techniques for Colon and Rectum —



| | |
|-----------------|---|
| Shinji Tanaka | Hiroshima University |
| Yoshiro Tamegai | Konodai Hospital, International Medical Center of Japan |
| Junro Tsuda | Fukuoka University Chikushi Hospital |
| Yutaka Saito | National Cancer Center Hospital |
| Naohisa Yahagi | Toranomon Hospital |
| Hiro-o Yamano | Akita Red Cross Hospital |

Towards the Standardisation of Colorectal ESD

Shinji Tanaka, Hiroshima University

Endoscopic submucosal dissection (ESD) is capable of en-bloc resection of lesions regardless of their size. This has not only enabled accurate histopathological examination, but also preservation of organs, already making it a standard treatment modality for early gastric cancer, particularly in Japan. ESD has also been listed as an insured treatment in Japan for superficial oesophageal cancer, as well as gastric cancer. However, ESD for colorectal cancer has not yet been established as a standard treatment modality, due to the difficulty of the techniques and because the pathological characteristics of colorectal cancer are radically different from those of oesophageal and gastric cancers. In view of this, the Working Group for Standardisation of Colorectal ESD was started as a subordinate organisation of the Japanese Gastrointestinal Endoscopy Promotion Liaison Committee in April 2006. The committee is presently clarifying the colorectal tumours for which ESD can be indicated, improving the endotherapy devices, endoscopes and ancillary equipment (focusing on those released by Olympus).

The majority of colorectal tumours are benign adenomatous lesions, and most early colorectal carcinomas have diameters of no more than 2 cm that can be resected by en-bloc EMR using a snare. Laterally spreading tumours (LSTs) are more difficult to resect with this technique. Since most granular-type LSTs (LST-G) are adenomatous even when they are large and accurate preoperative diagnosis is possible using magnifying observation, they can be cured completely with well-planned piecemeal EMR. It is important to have a good understanding of the particularities of colorectal anatomy and colorectal tumours and to avoid performing unnecessary ESD because of an inability to perform accurate qualitative diagnosis of tumours prior to the treatment. Since the colon is a long hollow organ, dysfunctions caused by local resection of regions other than the lower rectum are much less problematic than in the oesophagus or stomach, and the lower rectum can be also approved by transanal surgical resection. In large lesions the value of the ESD procedure, due to the operation time being too long, may also be questioned compared to laparoscopic colectomy.

At present, ESD can only be indicated for a small number of lesions due to the fact that the majority of colorectal tumours are adenomatous lesions. In addition, the technical difficulty of colorectal ESD is still quite high because of the difficulty in manoeuvring an endoscope with respect to the lesion, as well as the anatomic characteristics of the colon and rectum (thin wall and the presence of peristalsis, folds, bends, fecal fluid, etc.). For example, if the colon wall is perforated, there is a very high likelihood of peritonitis due to fecal fluid leakage — a complication that may require surgical treatment. Perforation of the stomach wall, on the other hand, can usually be cured with conservative management. The difficulty of colorectal ESD is determined more by how difficult the scope is to manoeuvre than by the size or visual shape of the lesion. It should be kept in mind that it is not acceptable to risk ESD in a situation where the scope is difficult to manoeuvre.

In closing, we hope that this booklet can assist the clinical studies of colorectal ESD that are being performed at an increasing number of hospitals. It is our wish that progress in ESD continues until it is standardised and that, by providing readers with the knowledge they need and discouraging them from attempting procedures that are too difficult, this booklet will support that progress by helping to prevent medical accidents that could hinder the development of colorectal ESD.

[Working Group for Standardisation of Colorectal ESD]

| | | | |
|----------------|--------------------------------------|-----------------|---|
| Shinji Tanaka | Hiroshima University | Yoshiro Tamegai | Konodai Hospital, International Medical Center of Japan |
| Junro Tsuda | Fukuoka University Chikushi Hospital | Yutaka Saito | National Cancer Center Hospital |
| Naohisa Yahagi | Toranomon Hospital | Hiro-o Yamano | Akita Red Cross Hospital |

Suggested Indications for Colorectal ESD

Among lesions that require en-bloc endoscopic resection, the following are considered to be indications for colorectal ESD.

- Lesions that are hard to resect en bloc using a snare:**
 - Laterally spreading tumours of the non-granular type (LST-NG), particularly the pseudo-depressed type.
 - Lesions presenting Type V₁ pit pattern.
 - SM carcinomas with scanty invasion.
 - Large depressed type tumours.
 - Large elevated lesions suspected to be carcinoma ^{*1}.
- Intramucosal lesions accompanied by submucosal fibrosis ^{*2}.**
- Sporadic local tumours located at chronic inflammations such as ulcerative colitis ^{*3}.**
- Local residual early carcinoma after endoscopic resection ^{*3}.**

Notes) *1. Includes tall laterally spreading tumours of granular type (LST-G).
 *2. Lesions caused by prolapse due to biopsy or lesion peristalsis.
 *3. Technical difficulty is high.

Supplement

- Both magnifying observation results as well as ordinary endoscopic observation should be used to determine whether or not colorectal ESD is indicated.
- In principle, SM carcinomas should be eliminated from the indication when invasion is clearly massive.
- With laterally spreading tumours of the granular type (LST-G), the treatment strategy should be based on the visually observed characteristics and the pit pattern diagnosis with magnifying observation as shown below. The large nodular area and Type V pit pattern area should not be divided.

Treatment strategy determination based on variations of LST-G

Homogenous type:

Endoscopic piecemeal resection (EPMR)



Nodular mixed type (1): Large nodules are present in limited areas.

Planned EPMR or ESD



Nodular mixed type (2): The entire lesion is formed by a large nodule.

ESD or surgical operation



• The treatment strategy can be determined as shown above. However, the actual determination of the treatment strategy should also take into account histological atypia and the skill of the endoscopist.

- A small SMT (submucosal tumours) localised in the submucosa can also be a target for indication.

Degree of Difficulty of Colorectal ESD by Region

| Region | Colorectal ESD Precautions According to Organ Characteristics |
|------------------|---|
| Rectum | Retroflexion is required. Special care is required in the rectum because it contains many more blood vessels than the colon. Careless retroflexion of the scope may pose a risk of perforation, so please pay attention when manoeuvring the scope. |
| Sigmoid colon | In this region, the scope tends to cause paradoxical movement, thereby making treatment difficult. As the lumen is narrow and bent, it is important to secure the field of view. (Advanced training required.) |
| Descending colon | Restricted scope manoeuvrability sometimes makes the procedure difficult. Please pay special attention to the area around the splenic flexure due to respiratory movement. |
| Transverse colon | The scope tends to cause paradoxical movement in certain areas. It is difficult to secure the field of view at the splenic flexure, middle transverse colon and hepatic flexure. (Advance training required.) |
| Ascending colon | In spite of respiratory movement, the lumen is relatively wide so it is easy to secure the field of view except in the area around the hepatic flexure. However, an extended procedure tends to cause deflection of the sigmoid colon. |
| Cecum | ESD is difficult because the wall is thin and the knife has to be applied perpendicularly to the thin wall. |

Subtypes of LST* lesions: Morphologic classification of LST lesions and their correspondence in the Paris-Japanese classification


Subtypes of LST Classification in type 0

LST granular (LST-G)

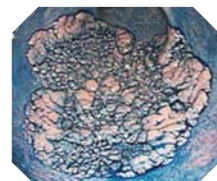
| | |
|--------------------|-------------------------------|
| Homogenous type | 0-IIa |
| Nodular mixed type | 0-IIa, 0-Is + IIa, 0-IIa + Is |

LST non-granular (LST-NG)

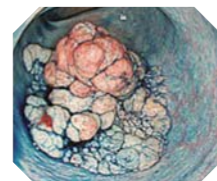
| | |
|-----------------------|--------------------------|
| Flat elevated | 0-IIa |
| Pseudo-depressed type | 0-IIa + IIc, 0-IIc + IIa |



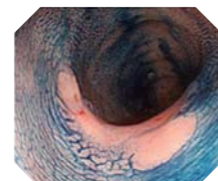
* The term "LST(laterally spreading tumour)" refers to the lateral growth of lesions at least 10 mm in diameter; this is in opposition to traditional polypoid (upward growth) or flat and depressed lesions (downward growth).



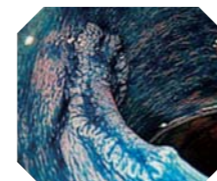
LST-G Homogenous



LST-G Nodular mixed



LST-NG Flat elevated



LST-NG Pseudo-depressed type

Reference: Shin-ei Kudo, René Lambert, et al. Nonpolypoid neoplastic lesions of the colorectal mucosa. *Gastrointest Endosc.* 2008 Oct; 68 (4 Suppl): S3-47

Notes on Colorectal ESD for First-Time Practitioners

The main reason for the technical difficulty of colorectal ESD is the difficulty of manoeuvring the endoscope with respect to the lesion. The anatomical characteristics of the colon and rectum (thin wall and the presence of peristalsis, folds, bends, fecal fluid, etc.) also add to the difficulty.

Perforation of the colon wall is a serious concern as there is a high likelihood of concurrent peritonitis due to fecal fluid leakage which may require surgery. Perforation of the stomach wall, on the other hand, can usually be treated successfully with conservative management.

The degree of difficulty of colorectal ESD is determined more by the manoeuvrability of the scope than by the size or shape of the lesion. Conducting the procedure in the same way as gastric ESD could produce a perforation. Before performing ESD for the first time, it is important to be acquainted with the particularities of the colon and rectum.

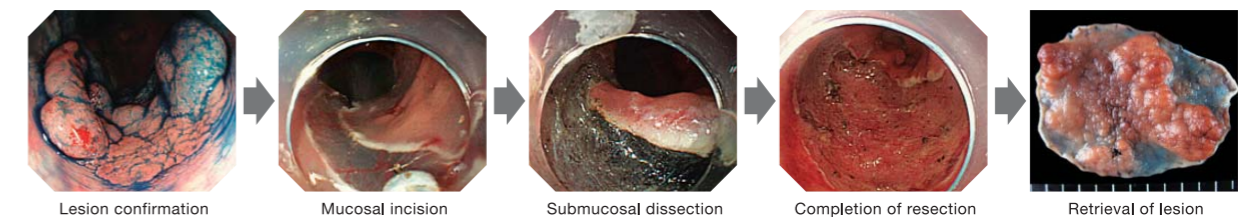
If the insertion technique based on total freedom of scope control has not been mastered, colorectal ESD should not be attempted. It is recommended that gastric ESD be tried first, and then an actual colorectal ESD be observed to understand how it differs from gastric ESD. Initially, colorectal ESD should be performed under the supervision of an expert endoscopist on a lesion with a low degree of difficulty — specifically, a relatively small rectal lesion in an area where scope control is relatively easy.

Please note that it is important to design an effective strategy before proceeding with colorectal ESD, including how and when to reposition the patient.

Recommended steps for mastering colorectal ESD techniques

- STEP 1** Master the handling of the scope, ancillary equipment, endotherapy devices and medications.
- STEP 2** Practice the scope manoeuvring technique until you can perform an upper gastrointestinal examination without difficulty.
- STEP 3** Master the colonoscopy insertion technique and the diagnostics.
- STEP 4** Learn the upper gastrointestinal and colorectal treatment techniques including the haemostasis technique, polypectomy, EMR and EPMR. Once you have successfully completed Steps 1 to 4, you are ready to safely perform a basic ESD procedure. You can then proceed to the following steps.
- STEP 5** Enhance your knowledge and technique by observing or assisting in actual ESD procedures, as well as by participating in simulations and various live demonstrations using animal models.
- STEP 6** Begin ESD by dissecting a lesion in the gastric antrum under the guidance of an expert endoscopist. Then master ESD of safe gastric lesions and the method of treatment of accidental symptoms. After completing these steps, you will be ready to perform oesophageal ESD and colorectal ESD with the highest degree of difficulty.


Flow of colorectal ESD techniques




- Thorough preparation is required before starting ESD.
- Marking is basically not required, as the extent of colorectal lesion can be distinguished easily.
- To ensure an efficient procedure, plan how to proceed with the incision and dissection beforehand.
- Apply local injection only to the area where you are about to incise. This will maintain the lifting effect of the mucosa.
- Incise the mucosa and then dissect the submucosa below it for a certain degree.
- Repeat the mucosal incision and submucosal dissection alternately until the whole lesion is dissected.
 - To extend the submucosa and ensure a smoother procedure, use local injections and adjust the patient's position as necessary.
 - Frequent haemostasis is required to maintain a clear view.
- Observe the ulcer floor after treatment and treat the vessels with the potentials of delayed bleeding with haemostatic forceps.

Hook Knife

Model KD-620QR/UR



- Basic specifications
- Distal end**
 - Cutting knife length: 4.5 mm
 - Hook length: 1.3 mm
 - Cutting knife diameter: $\phi 0.4$ mm
- Sheath**
 - Max. insertion portion diameter: $\phi 2.6$ mm
 - Working length: KD-620QR — 1,950 mm
 - KD-620UR — 2,300 mm



Electrosurgical settings and tips on using the Hook Knife

| Dr. Shinji Tanaka | Electrosurgical unit | ICC-200 | Cautions and Tips on Use |
|-------------------|-----------------------|------------------------|---|
| | Mucosal incision | EndoCut Effect 3, 80 W | <ul style="list-style-type: none"> ● It is important not to point the distal end toward the muscle layer. If the Hook Knife is activated while the distal end is contacting the muscle layer, perforation could easily occur. ● During dissection, hook the submucosa and pull the knife toward the center of the lumen and continue dissection. ● By contacting the submucosa with the Hook Knife when the submucosa is extended, you can create an edge to firmly hook the knife on. ● Although it is possible to use the ITknife or needle knife-style cutting technique with the Hook Knife, care is required because cutting this way can be risky if a good field of view is not secured. |
| | Submucosal dissection | Forced Coag., 40-50 W | |
| | Haemostasis | Forced Coag., 50 W | |
| | | | |

| Dr. Naohisa Yahagi | Electrosurgical unit | VIO300D | Cautions and Tips on Use |
|--------------------|-----------------------|---|--|
| | Mucosal incision | EndoCutQ, Effect2, Duration2, Interval2 or Dry Cut Effect2, 40W | <ul style="list-style-type: none"> ● Basically, manipulate the knife so that it is pointed toward the center of the lumen. ● When rotating the scope during the procedure, note that the orientation of the Hook Knife changes according to the rotation. Make sure to confirm the final orientation of the Hook Knife before manipulating it. |
| | Submucosal dissection | Swift Coag. Effect4, 40W | |
| | Haemostasis | Swift Coag. Effect4, 40W | |
| | | | |

| Dr. Yoshiro Tamegai | Electrosurgical unit | VIO300D | Cautions and Tips on Use |
|---------------------|-----------------------|---|--|
| | Mucosal incision | EndoCutQ, Effect2, Duration2-4, Interval4-6 | <ul style="list-style-type: none"> ● In my case, I incise and dissect the mucosa by keeping the Hook Knife projected a little from the scope and move the scope with a gliding motion, while keeping it a certain distance away from the lesion using an attachment. To ensure safety, I always move the Hook Knife carefully. ● Controlling the scope angulation and the torque allows you to handle the knife with the necessary precision. I try to straighten the scope so that the endotherapy device can be manipulated as intended. ● The high-frequency current should be supplied intermittently, and the foot should always be ready to release the footswitch to stop the current supply at any time. ● Safety can be assured by observing the hook portion at the distal end of the Hook Knife under the mucosa during the mucosal incision. During dissection, the distal end should be oriented toward the dissecting direction or to the opposite side of the proper muscle layer. The sweeping technique (intermittent current supply while tracing the back of the knife along the arc of the intestinal tract) is most used. Areas that need a delicate touch are dissected by hooking the tissue. |
| | Submucosal dissection | Swift Coag. Effect5, 50W | |
| | Haemostasis | Soft Coag. Effect5, 50W | |
| | | | |

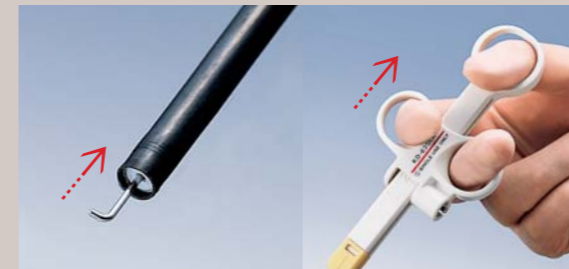
Case with Hook Knife



For Safer and More Appropriate Use

Information on this page provided by Olympus

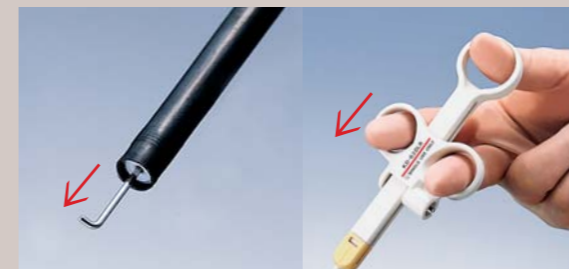Basic Operation of Hook Knife (Rotation)



- 1 Hold and pull the slider until the hook is slightly withdrawn. This makes the hook rotatable.




- 2 While holding the sheath, turn the handle slowly and align the direction of the hook.
 - *Rotation can be facilitated by removing the A-cord.
 - *If rotation is difficult, move the slider back and forth.



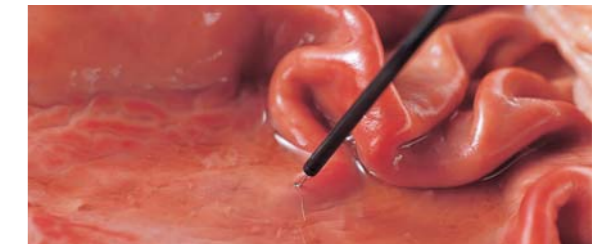
- 3 Push the slider and extend the cutting knife. By maintaining it, the rotation of the hook is locked.

Please note that under some conditions, damage such as melting of the distal end or stretching of the hook may occur. In particular, under the circumstances outlined below, an excessive load is likely to be imposed on the knife, increasing the risk that the knife will be damaged.



Conditions that impose a heavy load on the knife and countermeasures

- 1 When the current is activated while the knife is in contact with the tissue under high-moisture conditions:



☞ Before activation, remove moisture, including mucus and blood, from the region before contacting it with the endotherapy device.

- 2 When the electrosurgical unit is set to a high-voltage waveform and activation is continued for an extended period:

☞ Reduce the use of high-voltage waveforms to the minimum required level. Keep the activation period as short as possible when using a high-voltage waveform.*1

Electrosurgical unit: Voltage intensities of various waveforms

Cut / Soft Coagulation < Blend < Coagulation < Spray Coagulation*2 (e.g., APC mode)


*1 Long period of activation using a high-voltage waveform may increase invasion in deep tissue.
*2 Spray Coagulation mode cannot be used with this instrument.

- 3 When the knife is subjected to excessive force at the time of retraction into the sheath or during removal of tissue attached to the knife:

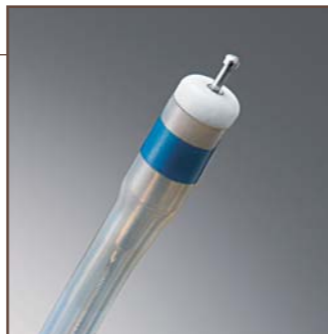☞ Be careful not to apply excessive force when removing tissue attached to the knife.

Dual Knife

Model **KD-650Q/U**



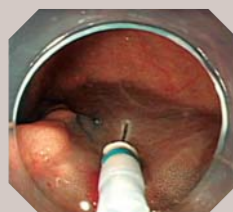
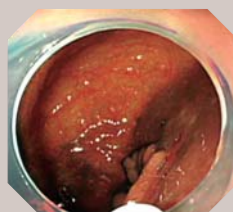
● Basic specifications
Distal end
 Cutting knife length: Extended — 1.5 mm
 Retracted — 0.3 mm
 Cutting knife diameter: ϕ 0.4 mm (except tip)
Sheath
 Outer diameter: ϕ 2.0 mm (max. ϕ 2.7 mm)
 Working length: KD-650Q — 1,950 mm
 KD-650U — 2,300 mm



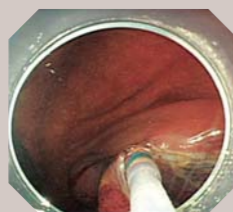
Electrosurgical settings and tips on using the Dual Knife

| Dr. Naohisa Yahagi | Electrosurgical unit | VIO300D | Cautions and Tips on Use |
|--------------------|-----------------------|----------------------------|---|
| | Mucosal incision | Dry Cut, Effect 2, 30 W | <ul style="list-style-type: none"> ● The knife should be fully extended during mucosal incision and submucosal dissection. When you retract the knife, haemostasis is possible by applying the current. ● Although the knife length is limited to 1.5 mm, the sharpness is very fine thanks to the needle shape of the knife. Rounded edges on the sheath's distal end improve contact with the area being incised. Be careful not to press the knife hard against the tissue during incision and dissection. ● The small tip on the knife makes it easier to hook the knife on the tissue. Hooking the tip on the tissue and manipulating the device as if stroking the tissue enables incision and dissection. ● If burnt tissue attaches to the knife during coagulation, frequently remove it using a moist piece of gauze. |
| | Submucosal dissection | Swift Coag. Effect 4, 30 W | |
| | Haemostasis | Swift Coag. Effect 4, 30 W | |

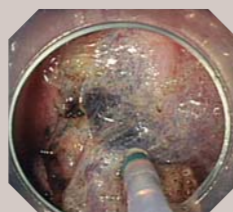
Case with Dual Knife



Mucosal incision



Submucosal dissection



Submucosal dissection

For Safer and More Appropriate Use

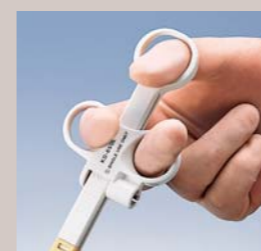Information on this page provided by Olympus

Basic Operation of Dual Knife

The Dual Knife can be adjusted in two ways, i.e., it can be retracted or extended depending on the requirement.

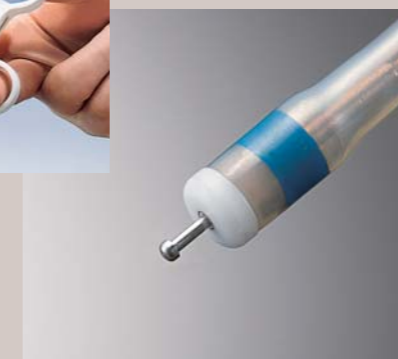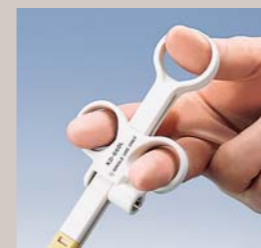When the knife is retracted

The Dual Knife can be used for marking and haemostasis. When the slider is pulled all the way, the knife will be withdrawn into the sheath with only 0.3 mm of the tip projecting.



When the knife is extended

The Dual Knife can also be used for mucosal incision and submucosal dissection. The knife is extended by 1.5 mm when the slider is pushed completely.



*The knife cannot be fixed in an intermediate position between the retracted and extended positions.

Please note that under some conditions, damage such as melting of the distal end or bending of the knife may occur. In particular, under the circumstances outlined below, an excessive load is likely to be imposed on the knife, increasing the risk that the knife will be damaged.

Conditions that impose a heavy load on the knife and countermeasures

1 When the current is activated while the knife is in contact with the tissue under high-moisture conditions:

☞ Remove moisture from the regions coming in contact with the endotherapy device, including mucus and blood, before activation.

2 When the electrosurgical unit is set to a high-voltage waveform and activation is continued for an extended period:

☞ Reduce the use of high-voltage waveforms to the minimum required level. Keep the activation period as short as possible when using a high-voltage waveform.*1

Electrosurgical unit: Voltage intensities of various waveforms

Cut / Soft Coagulation < Blend < Coagulation < Spray Coagulation*2 (e.g., APC mode)

*1 Long period of activation using a high-voltage waveform may increase invasion in deep tissue.

*2 Spray Coagulation mode cannot be used with this instrument.

3 When the knife is subjected to excessive force during removal of tissue attached to the knife:

☞ Be careful not to apply excessive force when removing tissue attached to the knife.

Coagrasper

Model FD-411QR/UR

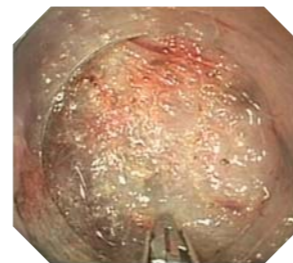


- Basic specifications
- Distal end
- Cup opening width: 4 mm
- Sheath
- Max. insertion portion diameter: $\phi 3.1$ mm
- Working length: FD-411QR — 1,950 mm
- FD-411UR — 2,300 mm



Electrosurgical settings and tips on using the Coagrasper

| | | | |
|---------------------|----------------------|----------------------------|--|
| Dr. Shinji Tanaka | Electrosurgical unit | ICC-200 | Cautions and Tips on Use <ul style="list-style-type: none"> ● The colon wall is thin and delayed perforation may occur if a wide area of the muscle layer is grasped. Try to grasp only a small point on the blood vessel itself as precisely as possible. ● If it is necessary to grasp the muscle layer, it should be grasped in such a way that you are grasping only the inner circular muscle. The muscle layer should be lifted slightly toward the inner side of the intestinal tract before activation. The most important thing with the colon and rectum is to avoid excessive activation. ● A scope with a water jet function is also essential in colorectal ESD to confirm the bleeding site and remove blood. |
| | Haemostasis | Soft Coag., 50 W | |
| Dr. Naohisa Yahagi | Electrosurgical unit | VIO-300D | Cautions and Tips on Use <ul style="list-style-type: none"> ● After rinsing the bleeding point with water and confirming its position, grasp the blood vessel, holding it at a single point. ● Grasp only the blood vessel, not the muscle layer. Lift the vessel slightly before activation. |
| | Haemostasis | Soft Coag., Effect 5, 50 W | |
| Dr. Yoshiro Tamegai | Electrosurgical unit | VIO-300D | Cautions and Tips on Use <ul style="list-style-type: none"> ● It is important to avoid excessive activation of the muscle layer as this could result in delayed perforation. ● Identify the bleeding point clearly, grasp the blood vessel at a single point, pull and apply intermittent activation for haemostasis. Avoid excessive activation of the muscle layer. Stop activation when the tissue around the bleeding point becomes white. When performing haemostasis on a perforator that penetrates to the muscle layer, restrict activation at a point before tissue whitening reaches the muscle layer. |
| | Haemostasis | Soft Coag., Effect 5, 50 W | |




For Safer and More Appropriate Use

Information on this page provided by Olympus

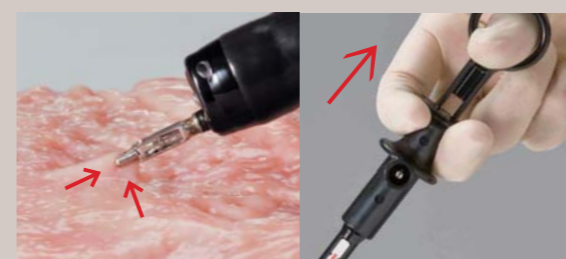Basic Operation of Coagrasper



- 1 Push the slider to open the cups.



- 2 Rotate the entire handle to adjust the orientation of the grasping forceps (clockwise rotation is smoother than counterclockwise rotation).



- 3 Guide the grasping forceps to the target region and grasp it. Lift the grasped tissue gently and supply high-frequency current.

Applicable forceps channel diameters



The Coagrasper for upper gastrointestinal applications (FD-410LR) can be used with a scope that has a channel diameter of 2.8 mm or more. The Coagrasper for colorectal use (FD-411QR/UR) should be used with a scope that has a channel diameter of 3.2 mm or more.

Why the applicable channel diameters are different

The Coagrasper for colorectal use (FD-411QR/UR) has a long working length. When it is inserted into a colonoscope while it is angulated, heavy pressure applied to the proximal end will cause deflection of the sheath. To prevent this, the proximal end of the sheath is coated with a reinforcing sheath, which increases the outer diameter of this part of the Coagrasper.



FD-411QR: to be used with I length colonoscopes only
FD-411UR: to be used with L length colonoscopes only

Q. Tips on Colorectal ESD Techniques

A.

Q1. Are there any precautions that you have to take in preparation?

Dr. Tanaka | The preparation should be as good as possible in order to reserve a good field of view during the ESD procedure and to reduce the risk of leakage of fecal fluid into the abdominal cavity in case of perforation.

Dr. Yahagi | We put the patient on a low-residue diet + laxative on the previous day, and administer 2 liters of Niflec® (oral lavage solution)*+ 10 ml of Gascon drops (defoaming agent)* on the day of the treatment.

Dr. Tamegai | Preparation is stricter than for an ordinary colonoscopy. We put the patients on a low-residue diet whenever possible before the treatment, and administer a larger amount of intestinal cleaning solution (Niflec®, etc.) than usual.

Q2. How do you sedate the patient?

Dr. Tanaka | Basically, we do not use sedation for colorectal ESD because the patient has to change position frequently.

Dr. Yahagi | We rarely use sedation for rectal ESD. When the patient feels a strong sense of distension in the deep part of the colon or is experiencing a lot of anxiety, we apply Opystan® (pethidine hydrochloride)* and add diazepam as required.

Dr. Tamegai | We use 10 mg diazepam at the beginning and maintain the sedation by intravenous injection of 35 mg Opystan® by 1/2 ampule. The total amount of Opystan® is variable depending on the procedure time, but we prepare 2 ampules of Opystan® before each procedure.

Q3. What is the name and composition of the local injection agent you use, and what precautions do you have to take for local injections?

Dr. Tanaka | We mix a small amount of indigo carmine with sodium hyaluronate (MucoUp®*) We also use Glyceol® (concentrated glycerin fructose)* when the condition is favourable. We begin local injection with Glyceol® to create a space in the submucosa, and then proceed to local injection of MucoUp®. This aims at avoidance of local injection inside the muscle layer.

Dr. Yahagi | Basically, we use Glyceol® (200 ml) + Bosmin (epinephrine)* (0.2 ml) + indigo carmine (0.2 to 0.4 ml). The dose of indigo carmine is basically low in order to improve the visual recognition of blood vessels. It is increased when fibrosis is present. With difficult cases, we add a local injection of MucoUp® + indigo carmine after tissue lifting using Glyceol®.

Dr. Tamegai | We generally use a stock solution of Glyceol® or MucoUp® according to the situation. We apply local injection from the mucosal side in the initial stage of incision and dissection, and then inject the solution directly into the submucosa after the dissection has advanced. Care is taken to avoid deep injection because extension of the submucosa would become difficult if the liquid is injected into the proper muscle layer.

Q4. Questions about haemostasis:

1. What do you use if there is bleeding during ESD, and how do you use it?

Dr. Tanaka | Minor bleeding can be stopped by coagulation using the distal end of the knife, but arterial bleeding should be treated with a haemostatic forceps (Soft Coagulation at 50 W). The colon wall is thin and delayed perforation may occur if a wide area of the muscle layer is grasped. As precisely as possible, only the blood vessel should be grasped (at a single point). If it is necessary to grasp the muscle layer, try to grasp only the inner circular muscle, and lift the muscle layer slightly toward the centre of the lumen of the intestinal tract before activation. The most important thing with the colon and rectum is to take care to avoid excessive activation.

Dr. Yahagi | Provided that the submucosa is sufficiently intact, bleeding from a small blood vessel can be stopped by coagulation using the distal end of the knife. When the bleeding is spurting or the muscle layer is exposed, bleeding should be stopped using haemostatic forceps. When doing this, a scope with a water jet function is very useful.

Dr. Tamegai | We treat bleeding at the oozing level with coagulation using the distal end of the Hook Knife, and use the Coagrasper to deal with spurting bleeding.

2. What device do you use to treat the blood vessels at the ulcer floor after ESD, and what is the objective of treatment?

Dr. Tanaka | We use a haemostatic forceps (Soft Coag., 50 W). We also treat the oozing area and the cut the end of the spurting artery using coagulation by grasping with a haemostatic forceps.

Dr. Yahagi | We apply coagulation using the Coagrasper to spurting bleeding or a thicker blood vessel. We apply the current till spurting stops and the tissue becomes white. Care is taken not to burn the tissue too much.

Dr. Tamegai | We treat thick exposed blood vessels using a short clip, and treat other small blood vessels with light coagulation using the Coagrasper or APC. The point of blood vessel treatment is to treat only the visible blood vessels from the ulcer floor, while leaving other vessels alone.

Q5. Questions about countermeasures against perforation:

1. What measures do you take to prevent perforation?

Dr. Tanaka | We use sodium hyaluronate (MucoUp®) in an injection solution and reposition the patient so that the injection solution can be pooled in the submucosal layer. Also, we take care not to contact the distal end of the Hook Knife with the muscle layer. When dissecting mucosa with the knife, we perform dissection using a gentle stroking technique on the submucosa, taking care not to touch the muscle layer and avoiding pressing the knife. We also take care not to risk ESD in regions where the scope is difficult to manoeuvre.

Dr. Yahagi | After making sure that the tissue is sufficiently lifted, we perform incision and dissection while checking the knife tip under the endoscopic view. Maintaining the field of view and keeping the tissue lifted are critical. Make sure that the knife contacts the tissue gently.

Dr. Tamegai | To avoid operating blindly, we try to incise and dissect only where we can observe endoscopically. Since the lesions with the highest risk of perforation in colorectal ESD are those accompanied with fibrosis in the submucosa, we believe it important to take measures according to the cause, type and severity of fibrosis. (Also see Q6 on Page 15.)

2. What kinds of countermeasures do you take if you end up with a perforation?

Dr. Tanaka | We treat small perforations with short clips. If the perforation is large, we also use a long clip sometimes.

Dr. Yahagi | Our first choice is a short clip (HX-610-090S), but we select the clip size and jaw angle according to the perforation size. When we find a perforation, we immediately clip it to prevent leakage of fecal fluid into the abdominal cavity. When releasing the clip, we exhaust air and close it gently (in order not to tear the muscle layer).

Dr. Tamegai | I have only experienced a small perforation, so I closed it with a clip. However, if the perforation is large, I believe it would be ideal to perform clipping in the same way as after EMR, that is, attaching indwelling clips to the edge of the perforation to make a spindle shape, then suture it by attaching clips from the easiest-to-clip position on the edge toward the centre. The clips we would use for this purpose are the HX-610-135 and HX-610-090L.

* May not be available in your area.

3. What kinds of countermeasures do you take if closure using clips is difficult?

Dr. Tanaka With a very small perforation, we exhaust air as much as possible, put the patient in a position so that the fecal fluid will not contact the perforation area, and administer an antibiotic. However, since perforative peritonitis is unavoidable if a perforation cannot be closed, it is important to prepare for emergency surgery by holding close communication with a surgeon. Perforation in a region without the serosa presents a high risk of formation of abscess on the retroperitoneum or around the rectum.

Dr. Yahagi We perform closure using an indwelling snare + clips if possible. If this is difficult, we perform surgery.

Dr. Tamegai I haven't had this problem so I cannot be specific, but I believe that a possible endoscopic approach would be to draw the greater omenta or soft tissues with negative pressure and close the opening with clips. However, as there is no established theory on what countermeasure to take when closure is difficult, so it may be appropriate to consider emergency surgery as the first choice.

4. What kind of equipment should we have on hand for use in the case of perforation?

Dr. Tanaka Clips for use in closure of perforations are indispensable. In addition, if a CO₂ insufflator is available, it is possible to reduce the intestinal pressure and therefore reduce the risk of leakage of fecal fluid into the abdominal cavity.

Dr. Yahagi A set of clips, a CO₂ insufflator and antibiotic are necessary.

Dr. Tamegai An abdominal ultrasound system should also be available in case deaeration is required.

5. What precautions do you take in postprocedural management of patients who have suffered a perforation?

Dr. Tanaka We manage the respiration and circulation dynamics in order not to overlook the abdominal observations (symptoms of peritonitis). It is also necessary not to miss the timing of emergency surgery in order to avoid hazardous consequences such as sepsis. Special care is required with elderly patients because they do not always present inflammation reactions or leukocytosis.

Dr. Yahagi Abstinence from food and drink is necessary. Fever can be reduced with continuous drip infusion and antibiotics. The patient should be closely observed until the inflammation reaction begins to decrease. Surgery should also be considered in the case of fever above 39°C, abdominal pain, or muscular defense.

Dr. Tamegai It is important to determine whether or not immediate emergency surgery is necessary based on the position and degree of perforation, the degree of contamination, and the effectiveness of clip closure. Consultation with the surgical team and measures in accordance with the risk management regulations are also necessary. If conservative management is possible, special attention should be paid to the fluctuation of vitals, the presence of signs such as muscular defense in abdominal observation, the presence of an abscess in CT or echo observation, and any changes in inflammation observed in peripheral blood and biochemical examinations.

Q6. What precautions do you take in resection of a fibrotic lesion?

Dr. Tanaka To make it easier to extend the fibrotic area of the submucosa, we start the incision and advance dissection from outside the fibrotic area. To improve visibility of the submucosa we inject it with indigo carmine. Dissection should be performed precisely, cautiously and gently using the Hook Knife. Do not risk proceeding in a situation where the submucosa cannot be recognised visually because advanced fibrosis is mixed into the muscle layer. In this case, you may have to consider stopping the procedure.

Dr. Yahagi Stay away from such a lesion if you are a beginner. Apply sufficient local injection, begin dissection from a point that's away from the fibrotic area, and enter the submucosa together with a distal attachment to ensure the direct endoscopic view of the scar area. Inject a sufficient amount of sodium hyaluronate around the scarred area to lift up the lesion as much as possible.

Submucosal fibrosis can be categorised into two types: 1) non-cancerous fibrosis with unknown cause, which is associated with treatment procedures such as local injection, biopsy and EMR as well as with inflammation and intestinal peristalsis; and, 2) fibrosis accompanying SM invasion of cancer. Non-cancerous fibrosis presents in endoscopic observation as a trabecular white tone with light fibrosis, a cingulated white tone with medium fibrosis, and a screen-type overall view with advanced fibrosis. Fibrosis accompanying cancer invasion appears white to brown, which may be the invading cancer cells, and has a large number of abnormal blood vessels. We applied ESD to 28 cases involving submucosal fibrosis, performing en-bloc resection on 21 cases and piecemeal resection on 5 cases. Resection in the last 2 cases was stopped before completion. In the cases in which ESD was completed, the factors that enabled resection were: 1) the injection solution succeeded in infiltrating the fibrous tissue stroma; 2) the dissection line could be set because the proper muscle layer position was identified from the normal or loose area around the fibrosis; and, 3) the distal end of the Hook Knife was able to enter the fibrotic tissue. On the other hand, we found that advanced screen-type fibrosis and advanced cancer invasion cases cannot be used as standard indications because local injection is not possible and there is no space for the Hook Knife to enter. Submucosal fibrosis can only be dissected when the boundary between the proper muscle layer and the submucosal layer can be identified and there is space for the knife to enter. In the operative field of view, it should be possible to identify the incision line by observing the fibrotic section and the lines of the proper muscle layer and the submucosal layer on both sides of the fibrotic section.

Dr. Tamegai

Usefulness of Carbon Dioxide (CO₂) Yutaka Saito, National Cancer Center Hospital

Carbon dioxide (CO₂) is absorbed in the intestinal tract more quickly than air, and reports from Europe and North America have demonstrated its safety and usefulness in reduction of patient discomfort. In addition, while insufflation of normal air sometimes produces feeling of distension and discomfort for about half a day after completion of the procedure, CO₂ gas reduces postprocedural abdominal discomfort.

Usefulness and safety of CO₂ insufflation in colorectal ESD

ESD sometimes lasts for many hours and patient discomfort due to excessive insufflation presents problems. We conducted colorectal ESD treatment with ordinary air insufflation and CO₂ insufflation, compared the results of two groups, and recognised a significant decrease in the usage amount of the sedative agent in the CO₂ group, without observing a rise in the blood CO₂ concentration. Later, we also measured the change in Ptc CO₂ value over time, and found that the average peak value was 56 mmHg. The rise over 60 mmHg is said to induce arrhythmia, but there were only a few cases and they were only transient. Although the risk of causing CO₂ narcosis is extremely low in colorectal examination under conscious sedation, the use of CO₂ should be avoided in patients with chronic obstructive pulmonary disease and serious heart disease. At present, we are able to safely conduct colorectal ESD under CO₂ insufflation using only oxygen concentration and electrocardiogram monitoring, except for patients with contraindications.

Reducing the risk of accidental symptoms in colorectal ESD

Even in the case of perforation, CO₂ can be absorbed quickly so the risk of subcutaneous emphysema can be prevented or reduced. CO₂ may also be useful in prevention of the abdominal compartment syndrome due to insufflation. In addition, while air embolisms have been reported as an occasional complication in endoscopic examinations, CO₂'s rapid absorption can be expected to reduce the risk of this complication.

Usefulness of the UCR


The Olympus UCR is capable of supplying stable CO₂ flow without complicated setup. Even if the operator makes a mistake in valve opening or closing, the UCR prevents rapid flow of CO₂ into the intestinal tract. Although it is more expensive than other gas regulators, it is very useful from the viewpoint of risk management.



ESD

Endoscopic Submucosal Dissection

— Techniques for Colon and Rectum —



Disclaimer: Any content or information ("Content") presented herein is illustrative in nature and does not guarantee or represent specific information, outcomes, or results. Olympus Corporation, its subsidiaries, affiliates, directors, officers, employees, agents, and representatives (collectively "Olympus") does not represent to or warrant the accuracy or applicability of the Content. Under no circumstances shall Olympus be liable for any costs, expenses, losses, claims, liabilities, or other damages (whether direct, indirect, special, incidental, consequential, or otherwise) that may arise from, or be incurred in connection with, the Content or any use thereof.