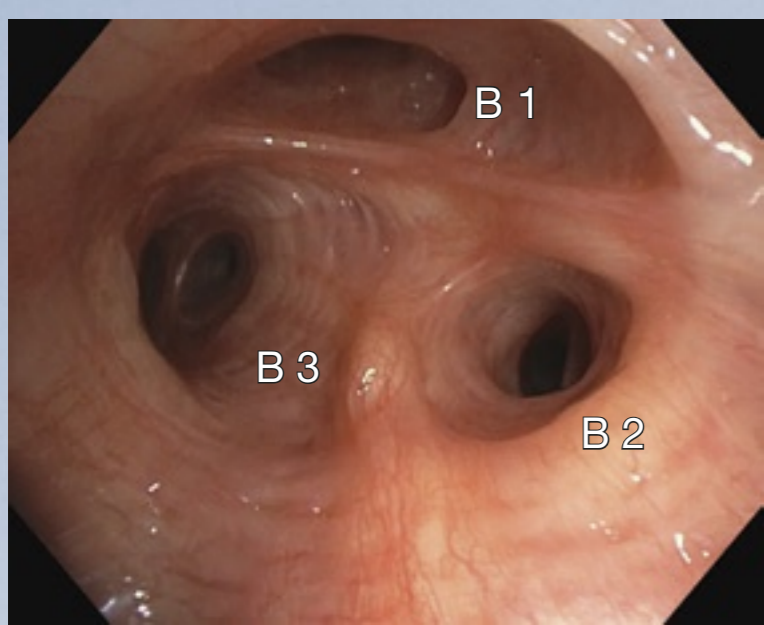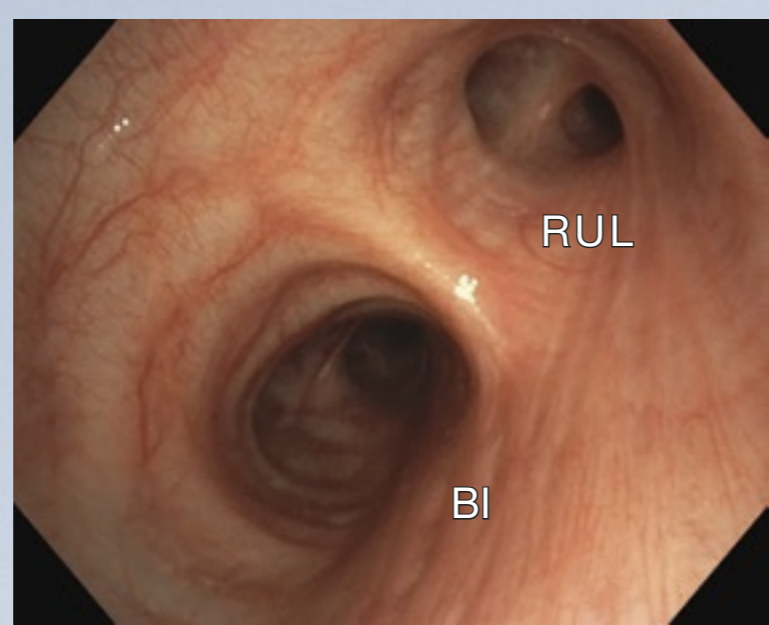
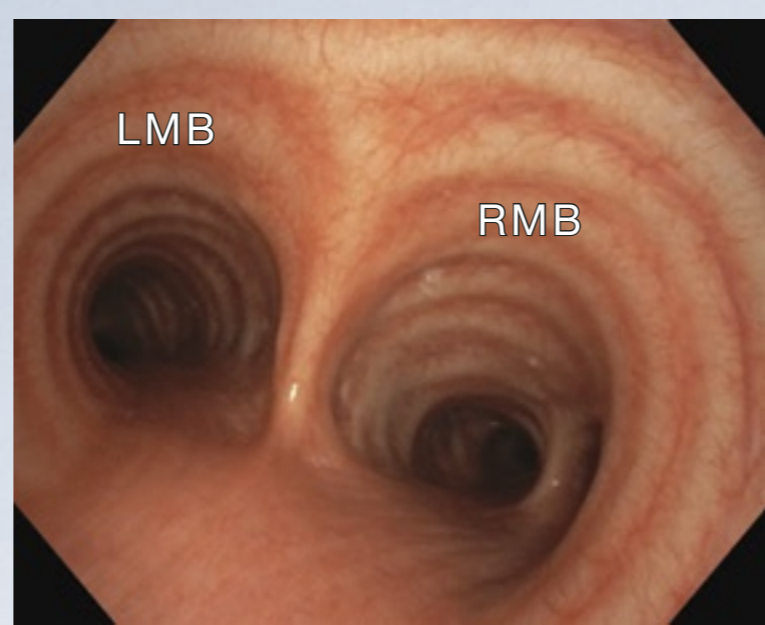


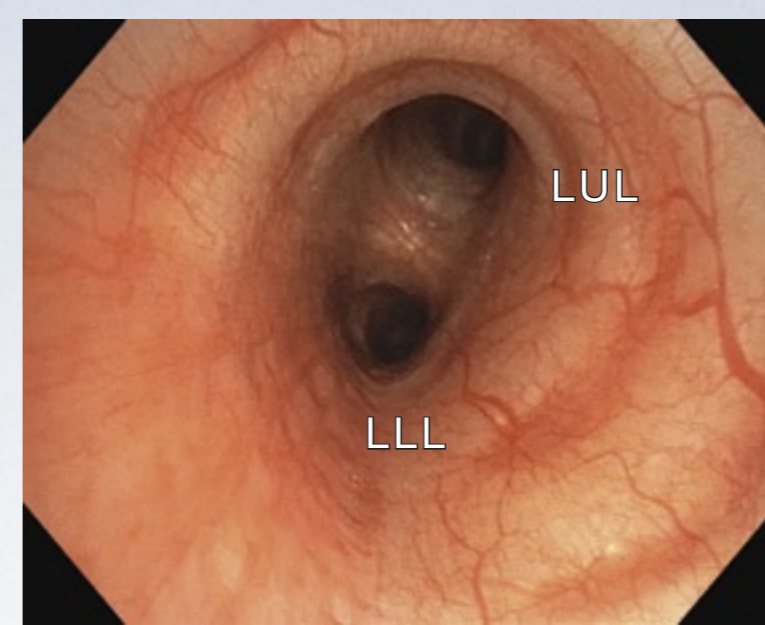
Right upper lobe



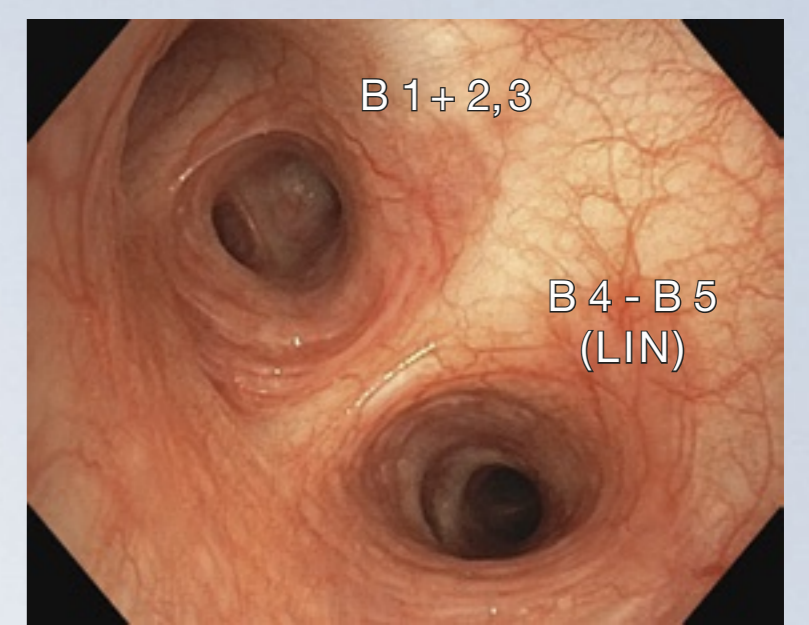
Right main bronchus



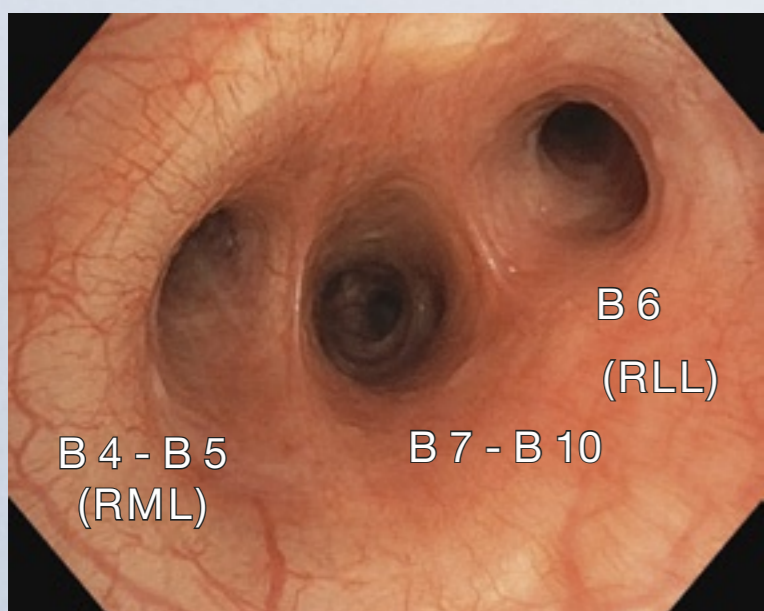
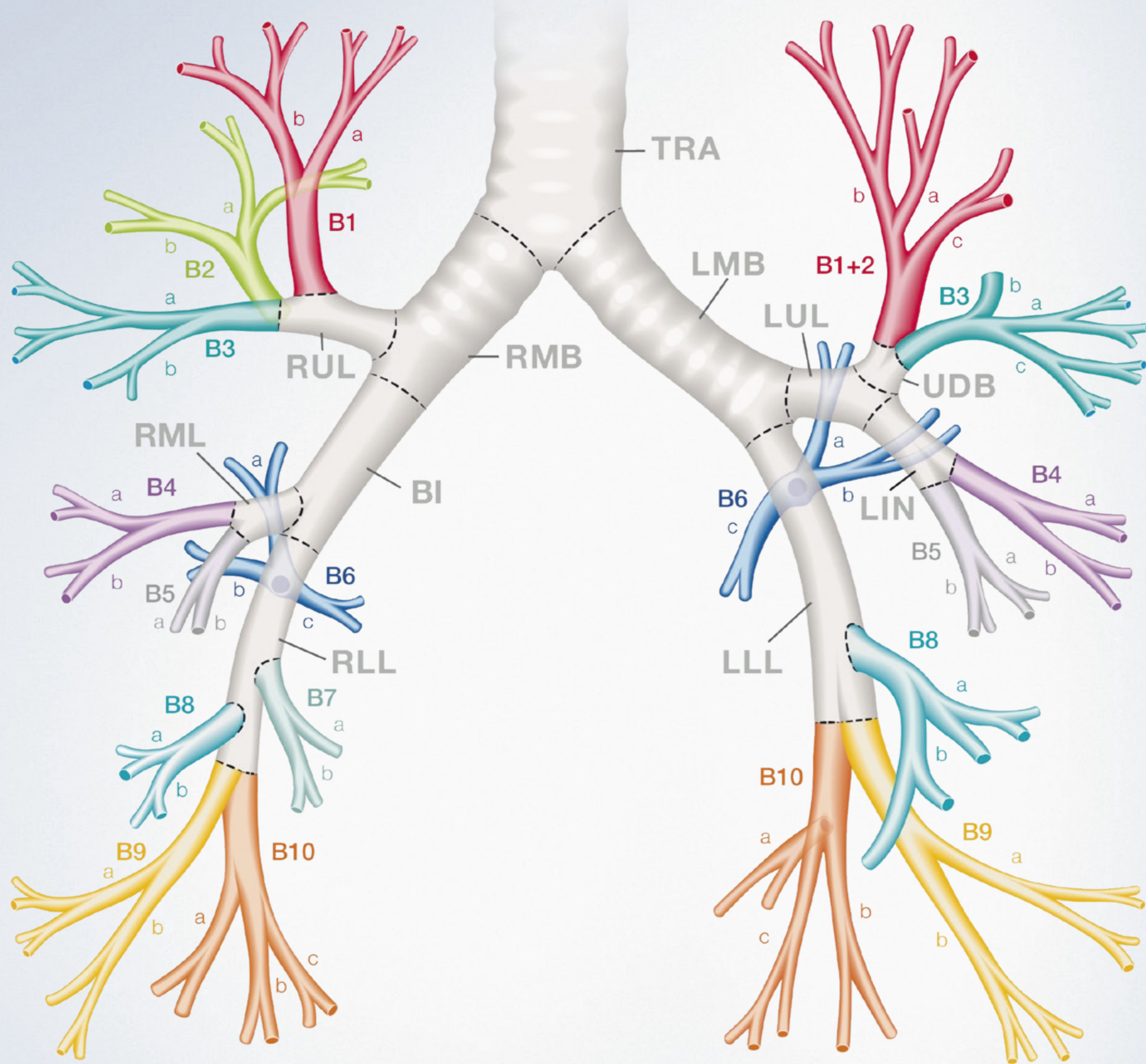
Main carina



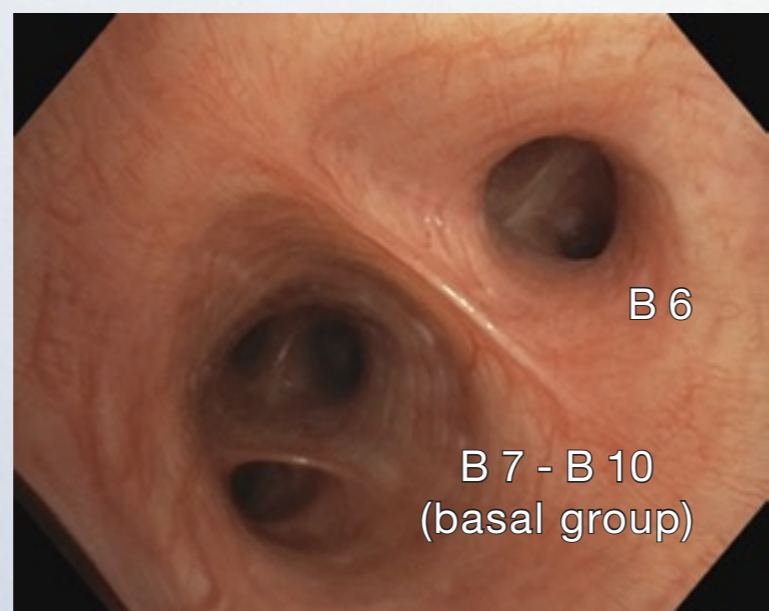
Left main bronchus



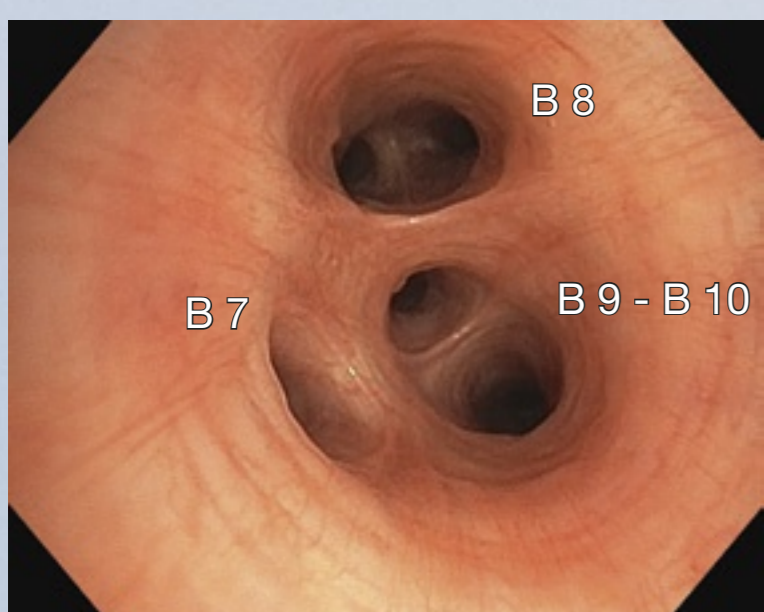
Left upper lobe



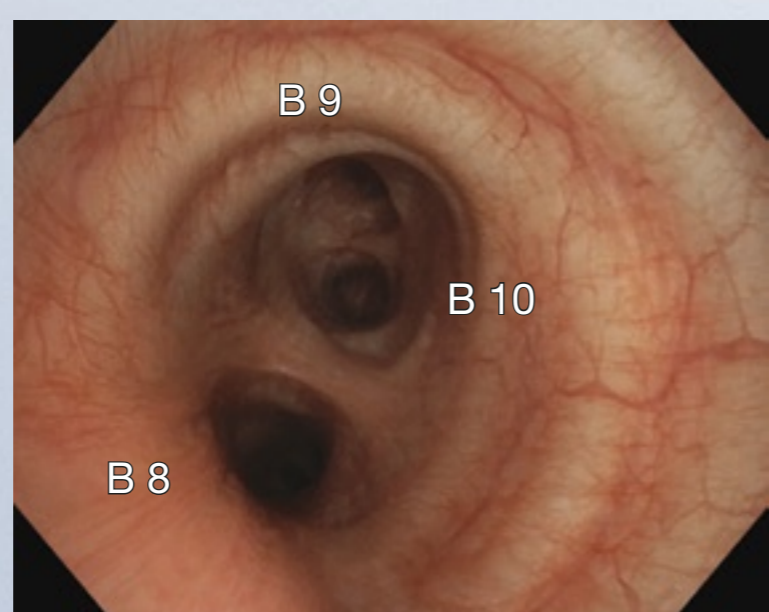
Bronchus intermedius



Right lower lobe (B6-10)

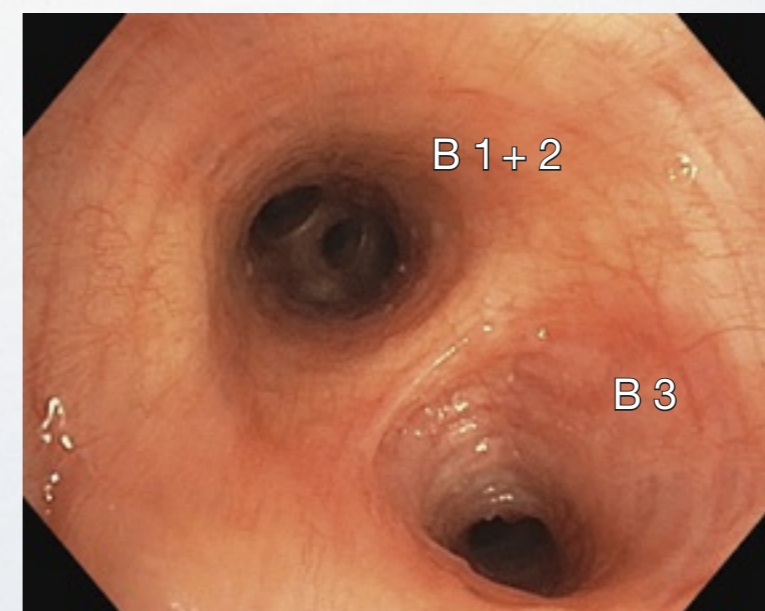


Right lower lobe (basal group)

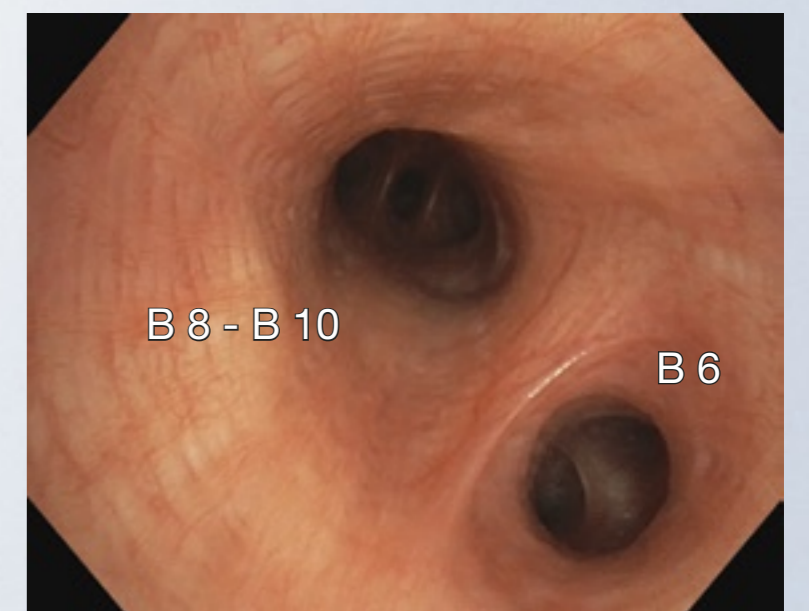


Right lower lobe (B8-10)

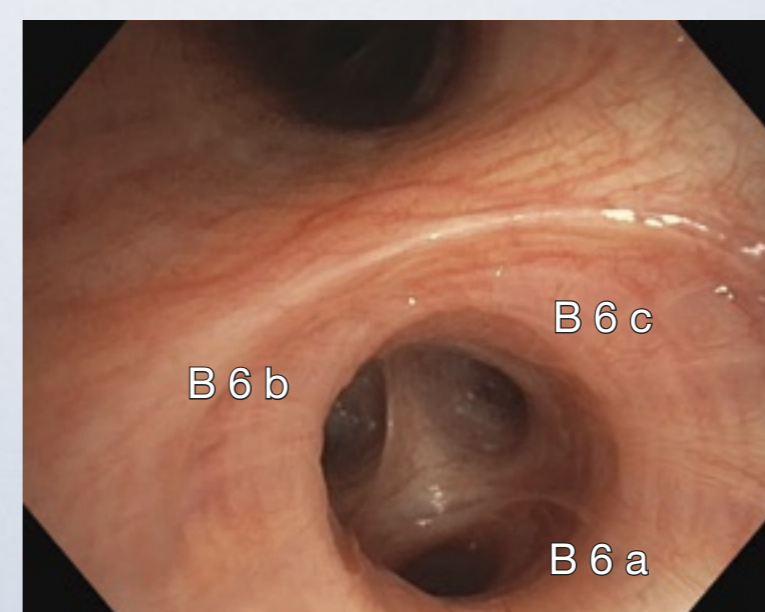
- TRA : Trachea / Main carina
- RMB : Right main bronchus
- RUL : Right upper lobe
- BI : Bronchus intermedius
- RML : Right middle lobe
- RLL : Right lower lobe
- LMB : Left main bronchus
- LUL : Left upper lobe
- UDB : Upper division bronchus
- LIN : Lingular bronchus
- LLL : Left lower lobe



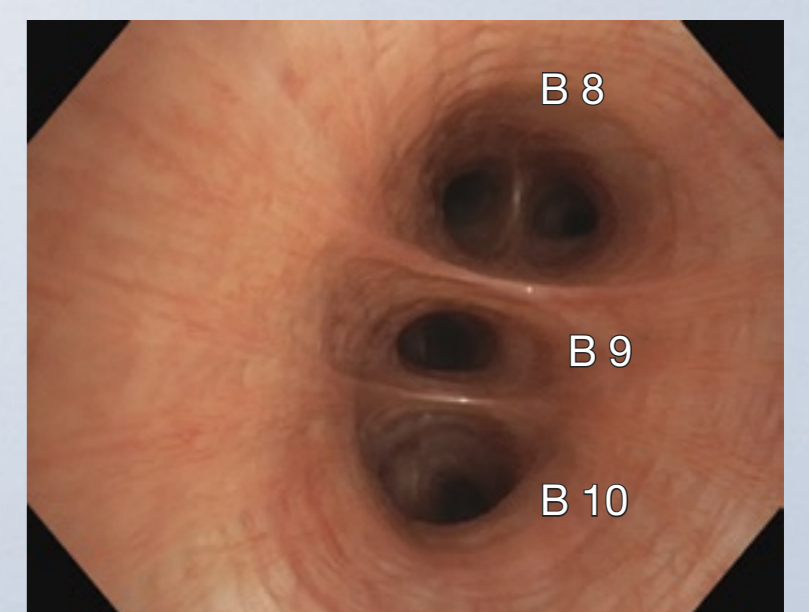
Upper division bronchus



Left lower lobe (B6-10)



Left lower lobe (B6)



Left lower lobe (basal group)

Clinical images provided by Prof. Dr. med. Ralf Eberhardt, MD, PhD, Thoraxklinik, University of Heidelberg, Germany

# Videobronchoscopy

## Nomenclature and Anatomy of the Bronchial Tree